



ISSN 1023-1072

Pak. J. Agri., Agril. Engg., Vet. Sci., 2016, 32 (1): 132-135

SHORT COMMUNICATION

SURGICAL REMOVAL OF A FIBROADENOMA IN A DOMESTICATED RAT (*RATTUS NORVEGICUS*): ORIGINAL CASE STUDY

I. H. Kathio¹ and A. N. Tunio²

¹Pittston Animal Hospital, 4 O'Connell Street, Pittston PA.18640, USA

²Department of Surgery and Obstetrics, Sindh Agriculture University, Tandojam, Pakistan

ABSTRACT

Fibroadenoma is a benign tumor composed of fibrous and glandular tissue. Mostly female rats have been victim of Fibroadenoma resulting from uterine abnormalities. Mammary fibroadenoma tumor occurs due to estrogen and prolactin hormone imbalance. Such types of tumors have been observed in older women. We report a clinical case of 3-years old female brown rat, showed soft mass on left lateral thorax region. Rat tumor surgery was performed under injectable anesthesia using Xylazine at 0.1 mg/kg and Ketamine 100 mg/kg plus Acepromazine 0.01 mg/kg body weight administered intramuscularly. CO₂ Laser (Luxar; model) was used to remove the tumor and wound was closed with Nylon 4-0 and skin staplers. It is concluded that histopathological findings of rat mass reported here confirm that adult rat has mammary fibroadenoma which is known as benign tumor.

Keywords: fibroadenoma, histopathology, rat, surgery

INTRODUCTION

Rat (*Rattus norvegicus*) is kept as pet animal and house-trained rats are physiologically and mentally different from wild rats (Merck Vet. Manual, 2008). Domesticated rats have no health risk of plague (Kathleen and Lathrop, 2003). Similarly rats like other animals become victim of different types of tumors on their bodies. Adenofibroma is a benign tumor which is composed of glandular and fibrous tissue and has been reported in women also (Maciel *et al.*, 2013). Fortunately, most of tumors in rats are benign and have been noticed in older age (Shafiuzama *et al.*, 2010). Mammary fibroadenoma tumor occurs due to estrogen and prolactin hormone imbalance (Mietes, 1972). Almost mammary

Corresponding author: ahmedtuniodvm2009@gmail.com

tumors are fibroadenoma which are benign (Percy and Barthold, 2007). It is important to remove tumors in rats. If tumors in pet rat are not removed timely that can lead to the death of animal. Therefore careful surgical management could be performed to save the life of animal. CO₂ laser surgery is one of the best choices to remove the tumors in rats, with minimum blood loss during surgery. This case presents the successful correction of mammary tumor in a rat.

MATERIALS AND MEHODS

Patient history and pathological findings

A 3-years old female brown rat (*Rattus norvegicus*) weighing 400 g was presented to the Pittston Animal Hospital, USA because of skin mass surgery. History reported that mass is growing since 2-months and increased gradually. The rat was found apparently healthy, bright alert and responsive (BAR) upon physical examination. The body score condition was (3/5). Upon clinical examination rat showed soft mass present on left lateral thorax region and mass was 6-cm in length (Plate 1). While animal had no any other deformities on its examination. The rat did not show pain on palpation of mass and differential diagnosis was hematoma and neoplasia. Surgical risk was discussed with owner of the animal. Rat was fasted for 12 hours and surgical site was prepared using antiseptic solutions and alcohol spray to prevent from infection.

Surgical correction

The rat was pre-medicated with Xylazine at 0.1 mg/kg body weight and anesthetized with Ketamine 100 mg/kg plus Acepromazine 0.01 mg/kg body weight intramuscularly. Lactating ringer's solutions 1-ml was administered subcutaneously. Rat was placed on right lateral recumbency and operative site was prepared as per routine. CO₂ Laser (Luxar; model) was used to excise the skin tumor (Plate 2). On gross examination, rat mass was vascularized and attached to the lateral thorax. The skin was closed with double suturing methods i.e. Nylon 4-0 and skin staplers. Recovery from anesthesia was safe and uneventful and rat recovered immediate after surgery (Plate 3). Post-surgery, the rat was treated with Torbugesic (2 mg/ml) 0.2 mg/kg administered intramuscularly to control post-operative pain. Terramycine ointment was applied on operative site. Rat was recovered 40 minutes post-surgery and discharged. Antibiotic Baytril 5 mg/kg was administered intramuscularly. After one week post-surgery skin wound was healed nicely. The rat had maintained a good condition and there was no any finding of recurrence of tumor following 3-weeks of surgery. The mass was submitted for histopathological confirmation. Upon gross examination mass was round and nodular. Tumor was light tan in color and tissue was 4.5x3.5 cm diameter. The tumor weight was 22 grams, it was hard in consistency and there was no extension of any mass with skin.

RESULTS AND DISCUSSION

Histopathological examination of excised rat mass from left lateral thorax section showed thinly encapsulated irregular multilobular proliferation. This proliferation was surrounded by epithelial cells arranged in small tubule-ductal patterns and acinar-like clusters supported by a moderate fibrous connective tissue stroma. The epithelial cells exhibit mild pleomorphism and low mitotic activity (0-1 mitosis

per 10 hpf). There was no evidence of lymphatic or vascular invasion seen. The microscopic examination of rat mass confirmed mammary fibroadenoma (Plate 4) which is known as benign type tumor. Majority of fibroadenoma tumors are benign type tumors and have been seen good prognosis on entire surgical removal. In this case it is reported that successful surgical correction of a thoracic tumor in rat was performed by excision of mass using CO₂ Laser (Luxar). Fibroadenoma is most common mammary tumor of rats occurred in old age (Percy and Barthold, 2007). According to Shafiuza *et al.* (2010) if such type of tumors not surgically removed in time, it will develop into large size resulting animal will suffer in movement. To control tumor in rodents animal feed should be low fat; calories diet and selection of disease free animal parent are key factors to prevent from fatal tumors. Prognosis was good post-surgery in this case. It is concluded that histopathological findings of rat mass reported here confirm that adult rat has mammary fibroadenoma and section appeared free from tumor cells.

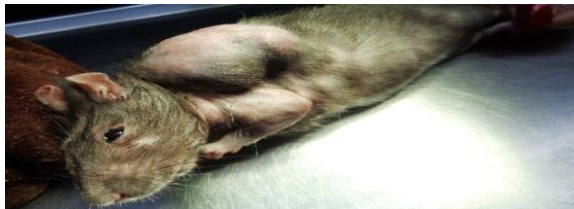

Plate 1. Mass on the lateral thorax of grey rat developed benign tumor on skin

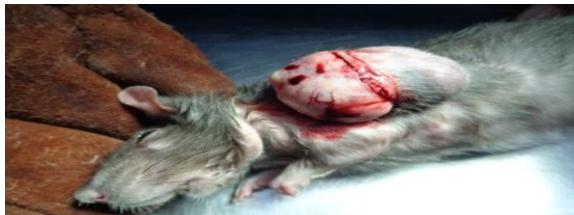

Plate 2. Intra-operative view of mass excised and measuring 4.5x3.5cm, on left thorax of a 3-years old female rat. Note: Drap was removed to showsurgical anatomy.

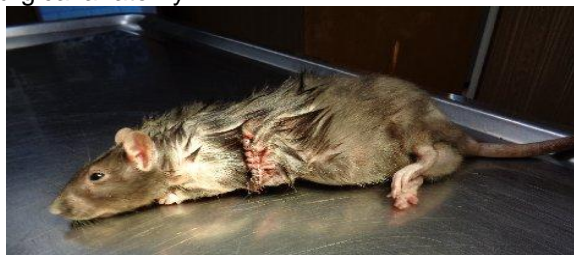

Plate 3. Post-operative view of rat. The mass was surgically removed and wound closed with nylon 4-0 and skin staplers

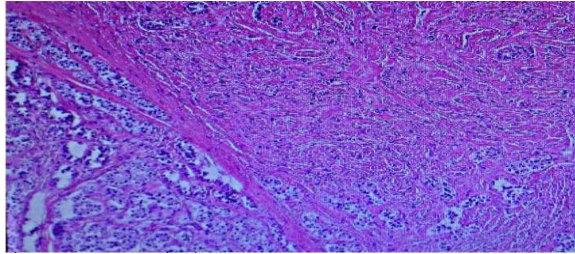


Plate 4. Histopathologic evaluation of the fibroadenoma removed from the left thorax rat explained in Plate 2. There is a proliferation closely packed epithelial cells arranged in tubo-ductal patterns. Acinear-like clusters are present which are supported by moderate fibrous connective tissue stroma. There is mild epithelial pleomorphism with low mitotic shape

REFERENCES

- Kathleen, A. and S. L. Lathrop. 2003. Plague: a veterinary perspective, *J.V.M.A.*, 222 (4): 444–448.
- Maciel, R., S. Carvalho, M. Teixeira and M. J. Areias. 2013. Adenofibroma in a young patient: A rare entity in an uncommon age. *Case reports in Obstetrics and Gynecology*, pp. 1-3.
- Merck Veterinary Manual. 2008. "Table on global zoonoses". *Neoplasia*" Merck and Co., Inc.
- Meites, J. 1972. Relation of prolactin and estrogen to mammary tumorigenesis in the rat. *J. Natl. Cancer Inst.*, 48 (4): 1217-1224.
- Percy, D. H and S. W. Barthold. 2007. Rat: *In. Pathology of Laboratory Rodents and Rabbits*, (3rd Ed), Blackwell Publishing Professional, Ames, Iowa, USA.
- Shafiuza, M., S. M. Simon, B. C. Das, G. D., Rao, T. A. Kannan and R. S. Kumar. 2010. Mammary Fibroadenoma in a rat and its surgical management. *Vet. World*, 3 (5): 235.

(Accepted June 03, 2016)