



EYE DERMOID IN A THARI BREED CATTLE CALF AND ITS SURGICAL MANAGEMENT: A CASE STUDY

A. Tunio¹, S. Bughio², S. H. Abro³, D. H. Kalhoro³ and A. A. Memon⁴

¹Department of Surgery and Obstetrics, ²Department of Veterinary Pharmacology, ³Department of Veterinary Microbiology, ⁴Department of Animal Reproduction, Sindh Agriculture University, Tandojam, Pakistan

ABSTRACT

A white colored 1-month-old Thari breed cattle calf was brought in the Veterinary Surgery Clinic of Sindh Agriculture University Tandojam for surgery (Surgical manipulation), because of dermoid tissue development on both the eyes by birth. The physical examination of eye showed a dermoid tissue development on both eyes. Dermoid tissue of approximately 1cm size was formed on lower part of eye lid in cornea, causing irritation of eye ball and mild signs of pain on direct palpation. The calf was sedated with 20% Xylazine HCl @ 0.05 mg/kg body weight intravenously. The animal was placed in right lateral position for surgical intervention on a table. Local anesthetic 2% Lidocaine HCl @ 4ml per side was injected locally at site of incision and manipulation. The surgical site was washed with disinfectant and, hairs around eye were removed. Dermoid tissue on lower eye lid was grasped with curved artery forceps and was excised gently by superficial keratectomy procedure. There was no bleeding and then wound was closed with Safil 5/0 (Polyglycolic acid) absorbable suture. It is reported that eye dermoid is genetically transmitted diseases in animals. In conclusion corneal dermoid surgery can be performed using Xylazine and lidocaine by superficial keratectomy procedure.

Keywords: cow calf, eye dermoid, lidocaine, surgery, xylazine

INTRODUCTION

Dermoid tissue formation in eyes of animals is a benign tumor and defect shows normal tissue formations at improper place (Erdikmen *et al.*, 2013; Roh *et al.*, 2014; Abu-Seida, 2014). Dermoid is a chrostoma tissue development and found at third eye lid, cornea and on eye lids which is corrected by surgical procedure (Mudasir *et al.*, 2012). If dermoid tissue is not removed by surgical procedure that defect will interfere with the eye sight and may result-in permanent defect in eye (Roberts and Lipton, 1995). Therefore, superficial keratectomy procedure is used to correct such types of eye defects (Kalpravidh *et al.*, 2009). Dermoid can easily be diagnosed on physical examination. This case study deals with the surgical removal of dermoid tissue of eye in a Thari cattle calf.

Corresponding author: ahmedtuniodvm2009@gmail.com

MATERIALS AND METHODS

Case history

A one month old female cow calf was brought to Veterinary Surgery Clinic of Sindh Agriculture University Tandojam. Upon physical examination of a calf, a mass of dermoid tissues developed was found at birth on both eyes. Both eyes were defective and soft skin mass 1-inch size was attached on cornea and it was irritating to eyes. On physical examination, animal was bright alert and responsive. This mass was demarcated and surrounded by a skin tissue with hairs. There was no eye infection, swelling or growth related to the mass. Close examination showed that dermoid mass was attached with cornea and irritating to eye and resulting lacrimation (Plate. 1A). It was planned for surgical removal and operation risk was discussed with owner and he consented for surgical procedure.

Preoperative preparation

Cow calf was sedated with Xylazine HCl (20 mg/ml) at 0.05 mg/kg body weight intravenously. After sedation the calf was placed on right lateral position. Eye lid nerve block was made by local infiltration of 4ml 2% Lidocaine HCl to reduce local pain around the site of incision. However, this local anesthesia does not provide analgesia to eye ball, therefore additional 1-ml of 2% lidocaine HCl solution was diluted with 3-ml of sterile water and then injected 1-ml in eye dermoid mass. The eye mass was irrigated with 0.9% normal saline solution.

Surgical approach

After anesthesia the dermoid tissue at lower eye lid was grasped with curved artery forceps and an elliptical incision was made over the eye mass. Exposed dermoid tissue was surgically removed using surgical blade No.10 and scalpel handle No.3 (Plate. 1B). Excised eye (dermoid) tissue was separated from left eye of a cow calf (Plate. 2 A) and eye wound was sutured using Safil 5/0 (Polyglycolic acid) absorbable suture material. Post-surgery eye was looking normal (Plate. 2B). Upon the request of animal owner, right eye dermoid surgery was performed after 2 weeks interval with similar procedure. After surgery animal was able to stand and walk slowly. Animal was treated with injection of Dexamethasone (2 mg/kg) 1-ml, Procaine Penicillin-G 1-ml IM route and Betnosol-N (Betamethasone sodium phosphate / neomycin sulphate) eye drops were used for three days. The calf was examined weekly for four weeks post surgery to find out any complications or recurrence of dermoid tissue in eye.

RESULTS AND DISCUSSION

Eye dermoid is known as congenital defect (Roh *et al.*, 2014) and is commonly removed by surgery (Mudasir *et al.*, 2012). This case study reported here deals with clinical examination, findings, surgery and outcome of this case in cow calf. A normal skin tissue formation at lower eye lid in a cow calf was observed and hairs were irritating to the eye ball (Plate. 2A). However, a dermoid tissue was attached with conjunctiva along with mass and hairs. Further, there was no ulceration or growth seen on both eyes of animal. Based on physical examination it was diagnosed a bilateral dermoid tissue formation on both eyes. In this case a surgical correction of both eyes dermoid was performed using partial

keratectomy procedure. Six days post-surgery follow-up observation was carried out and it was found that eye wound was healed. There was no more growth or complication observed at operated site and eye movement of calf was normal. Eating and drinking of animal was better.

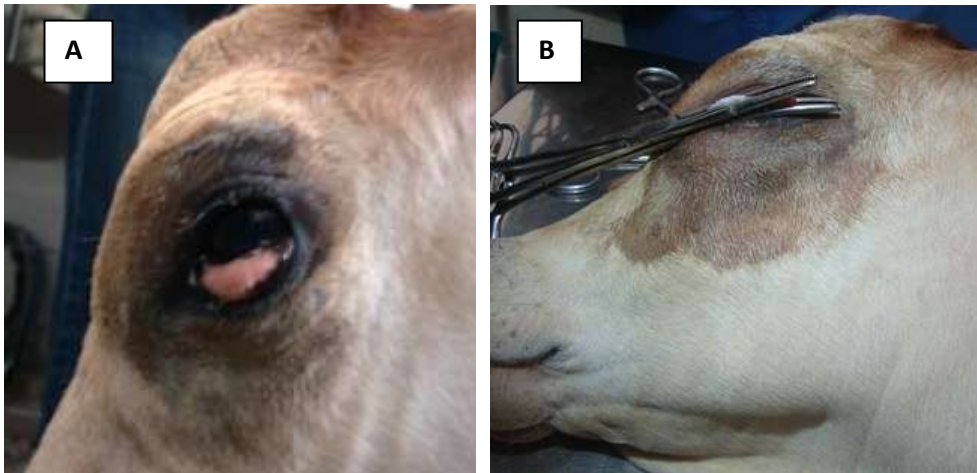


Plate 1. Before surgery dermoid cyst was visible on lower eye lid in between direction of 3 and 6 o, clock of the left eye in a cow calf (A). Dermoid tissue was surgically removed from left eye (B).

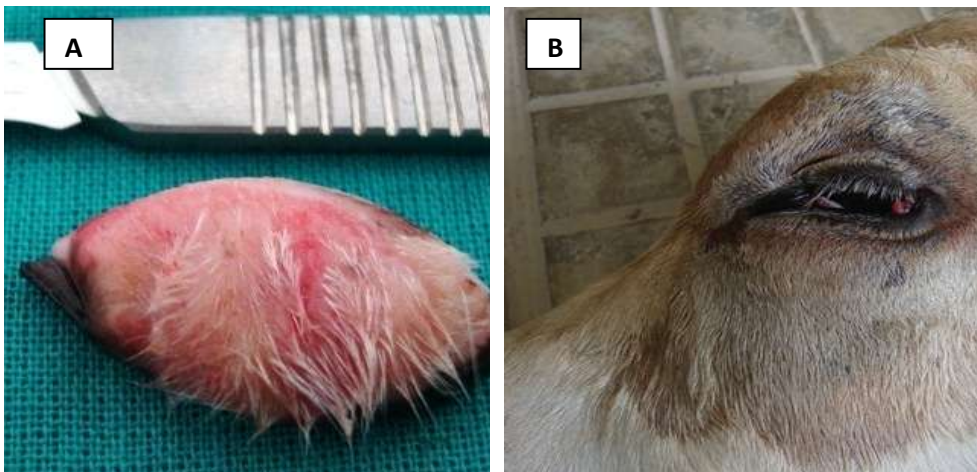


Plate 2. Excised dermoid tissue from left eye of a cow calf showing hairs and skin (A) After surgery left eye showing defect removed and eye in normal condition in a cow calf (B).

Two weeks of post-surgery the wound was completely healed and no eye discharges were observed. After one month examination calf did not show any sign of re-occurrence of dermoid on both eyes. Maggs (2003) and Martin (2005)

described that dermoid is a choristoma of normal tissue formation at abnormal location. It is a congenital over-growth of heterotropic defect which appears at incorrect site of eye (Brudenall *et al.*, 2007; Cook, 2007; Sarrafzadeh *et al.*, 2007). While, mechanism of eye dermoid formation is not known (Barkyoumb and Leipold, 1984), but in man it is reported that eye defects are hereditary (Laibson and Waring, 1975). Our findings in this case are in agreement with Williams and Gellat, (1981) who reported that eye dermoid defect may occur in cattle on one or on both eyes.

Findings of this case study are in agreement with the reports by Weber and Van (1990); Sarrafzadeh *et al.* (2007) that eye dermoid is a malformation which appear in eye with resembling to normal skin tissue. However, eye dermoid is composed of dermis like tissues which contains skin, hair follicles that are usually attached with cornea and conjunctiva (Ismail, 1994). Findings observed in this case are in agreement with the case report and by Pandey *et al.* (2011) they found skin tissue and hairs attached to cornea and frequently irritate eye of the animal which leads to conjunctivitis and Plate 2A shows similar findings. While reports of Dice, (1980) and Shiju *et al.* (2010) support our case study that dermoids defect is usually removed by surgical procedure in animals. Therefore similar surgical procedure performed on a cow calf eye dermoid defect was corrected in this study. Further, Abu-Sieda (2014) reported that surgical procedure is a key solution to be used for removal of corneal dermoid defect. Corneal congenital defect has been seen in many farm and pet animals, therefore complete removal of eye dermoid can be performed using surgical procedure.

CONCLUSION

It is concluded that corneal dermoid surgery can be performed using 20% Xylazine HCl which produces safe sedation and analgesia. In addition, 2% lidocaine HCl which is a local anesthetic which produces a good local analgesia for surgical removal of eye dermoid in a cow calf. This combination could be useful for corneal dermoid correction in clinical cases of animals.

REFERENCES

- Abu-Seida, A. M. 2014. Corneal dermoid in dogs and cats: A case series and review of literature. *Global. Vet.*, 13 (2): 184-188.
- Barkyoumb, S. D. and H. W. Leipold. 1984. Nature and cause of bilateral ocular dermoids in Hereford cattle. *Vet. Patho.*, 21 (3): 316-324.
- Brudenall, D. K., M. E Bernays and Jr-R. L. Peiffer. 2007. Central corneal dermoid in a Labrador retriever puppy. *J. Small Anim. Pract.*, 48: 588-590.
- Cook, C. S. 2007. Ocular embryology and congenital malformation. *In: Gelatt K.N (ED): Veterinary Ophthalmology*, 4th ed. Blackwell, Oxford.pp. 21-22.
- Dice, F. P. 1980. Primary corneal disease in the dog and cat. *Vet. Clin. North. Am. Small Anim. Pract.*, 10: 339-356.
- Erdikmen, O. Dilek., A. Didar, S. Murat, G. Ozlem, H. Hasimbegovic, E. Asli, G. Aydin and G. Y. Ozturk. 2013. Surgical correction of ocular dermoids in dogs: 22 cases." *Kafkas. Uni. Vet. Fak. Derg.*, 19 (Suppl-A): A41-A47.
- Ismail, S. F. 1994. Ocular dermoids in some farm animals. *Assiut. Vet. Med. J.*, 30: 212-220.

- Kalpravidh, Marissak, T. Pranee, V. Simon and S. Sudson. 2009. Canine amniotic membrane transplantation for corneal reconstruction after the excision of dermoids in dogs. *Vet. Res. Commun.*, 33 (8): 1003-1012.
- Laibson, P. R. and G. O. Waring. 1975. Disease of the cornea. *In: Pediatric Ophthalmology*, (ed. Harley). W.B.Saunders Company, PA. pp. 273-325.
- Maggs, D. J. 2003. Conjunctiva. *In: Slatter, D.J. (Ed): Text book of Small Animal Surgery*. 3rd Ed., Saunders, PA. p.1346.
- Martin, C. L. 2005. Conjunctiva and third eye lid. *In: Ophthalmic disease in veterinary medicine*, Manson publishing Ltd., London. p. 204.
- Mudasir, Q., K. A. Shah and A. Andrabi. 2012. Successful management of corneal dermoid in a cross bred calf. *Vetscan.*, 7 (1): 111-113.
- Pandey, S. S., B. Bharti, A. Patidar and N. Shukla. 2011. Surgical correction of corneal dermoid in a cross bred calf. *Vet. Practitioner*, 12 (1): 32-33.
- Roberts, S. R. and Lipton. 1995. The eye in feline medicine and surgery. *In: Cattcot, E. J. (Ed) 2nd Eds*, Am. Vet. Publications.
- Roh, Y. S., D. B. Gi, C. W. Lim and B. Kim. 2014. Asymmetrical ocular dermoid in native Korean cattle. *J. Anim. Plant. Sci*, 24 (3): 976-978.
- Sarrafzadeh, R. F., A. A. Farshid and S. Saifzadeh. 2007. Congenital ocular dermoid cyst in a river buffalo (*Bubalus bubalis*) calf. *J. Vet. Med.*, 54 (1): 51-54.
- Shiju, S., M. B. Justin, Willam, G. D. Rao, R. Sivashankar and K. Suresh. 2010. Congenital malformation in ruminants and its surgical management. *Vet. World*, 3 (3): 118-119.
- Weber, A. and H. W. Van. 1990. A corneal dermoid in a black wildebeest *connochaetes gnou*. *J. Koedoe-Afr. Prot. Area Conserv. Sci.*, 33 (2): 99-101.
- Williams, L. W. and K. N. Gellat. 1981. *Textbook of Veterinary Ophthalmology*. Lea and Febiger, PA. pp. 606-648.

(Accepted August 15, 2016)